AVINENT®
EXPERIENCES

SHARING KNOWLEDGE ABOUT
**DIGITAL DENTISTRY**

CLINICAL CASE

# Creating emergence profiles in immediate implant dentistry


AUTHORS

**Dr. Daniel Capitán Maraver**

**Dr. Manuel Fuentes Ortiz**

Visiting lecturers in the Master's Degree in Clinical Practice in Implantology and Oral Prostheses, University of Barcelona


AVINENT®
Implant System

CLINICAL CASE

## Creating emergence profiles in immediate implant dentistry

The current esthetic demands presented by many patients have led to updating success criteria in dental implants in the anterior region and now involve not only osseointegration of the implant, but also the long-term peri-implant stability of hard and soft tissue.

This peri-implant stability may be compromised when there is already tissue loss resulting from the inevitable remodeling of post-extraction sockets. It is for this reason that when dealing with the anterior region, we have to view therapeutic options that can help us to reduce or compensate the inevitable remodeling of the post-extraction socket by means of alveolar regeneration or immediate implant dentistry.

Our commitment to the patient is to be able to compensate for the loss of hard and soft tissue so that 3D positioning of the implant is correct, the hygiene and esthetics of the implant-supported crown is optimal and the reliability of our treatment is not compromised in the long term.[1]

The role played today by immediate implant dentistry and immediate loading in the anterior region [2, 3] is of paramount importance in order to understand that any surgical procedure to position an immediate implant implies correct management of the socket, mucosa and design of the provisional prosthesis until obtaining the final crown.[4, 5, 6]

We are therefore faced with what is known as a “surgery-periodontology-prosthetic balance”, in which the three specialties will be responsible for providing us with a reliable long-term result when dealing with the anterior esthetic region.

CLINICAL CASE

## Creating emergence profiles in immediate implant dentistry

Below is a clinical case of coronal fracture of tooth 11 with periapical lesion showing tooth extraction. Two treatment options were here taken into account:

**Option 1:** Tooth extraction with alveolar regeneration and deferred implant positioning

**Option 2:** Tooth extraction with immediate implant positioning

Following clinical, radiographic and tomographic examinations, it was decided to proceed with the extraction of tooth 11, immediate implant and immediate esthetic loading in order to be able to control and compensate for bone and soft tissue remodeling of the post-extraction area.[1]

Initial orthopantomograph of patient

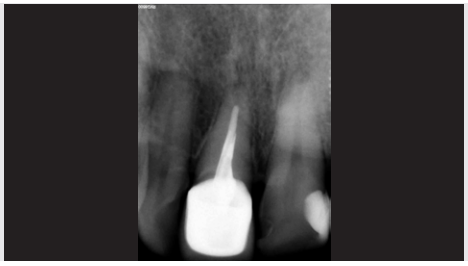

Prior panoramic X-ray of tooth 11

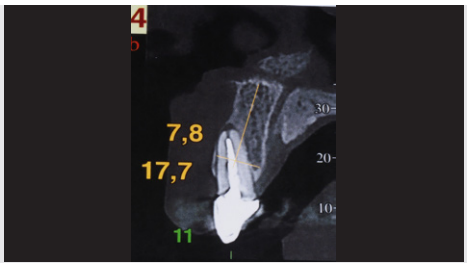


Orthoradial section of CBCT corresponding to tooth 11 showing apical lesion and palatal triangle of bone that can provide primary stability to our implant

Extraoral photograph showing a low-medium smile with slight extrusion of tooth 11

Intraoral photograph showing loss of papillae with gingival margin of coronal 11 to 21, which must be preserved, and thick biotype with square-shaped tooth

Detail of thick gingival biotype

CLINICAL CASE

## Creating emergence profiles in immediate implant dentistry

Tooth 11 was extracted and an AVINENT Implant System Biomimetic Ocean (3.5 x 13 mm) implant was positioned, prosthetically guided by a surgical guide made of resin that provided correct 3D positioning of the tooth to be restored and would simultaneously serve as an immediate loading provisional crown.

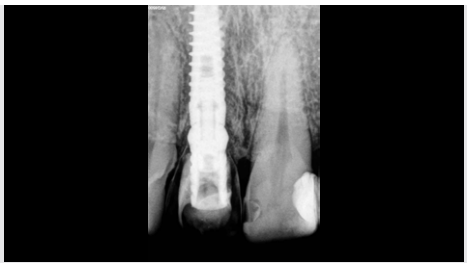

Post-surgery panoramic X-ray of Ocean implant with provisional crown

Provisional crown 4 months after implant placement with maintenance of gingival levels

Occlusal intraoral photograph of provisional crown at 4 months showing maintenance of gingival architecture

Removal of provisional crown showing good gingival health

Insertion torque was 45 Ncm, the implant holder was removed and the implant was grinded to be able to line it with the provisional crown of the surgical guide. Following the critical and subcritical contour guidelines established by Óscar González,[7] the provisional crown was screwed on and the implant holder was lined, previously having been painted with opaque so that the provisional crown could be left for a total of 4 months, thereby adequately handling the mucosal contour. After the third month of loading, the emergence profile was modified to obtain the current mucosal level.

View of gingival volume maintenance

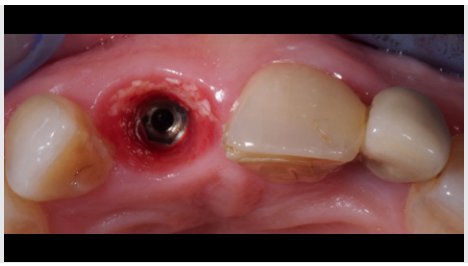

Detail of gingival health showing full vestibular integration of biomaterial

Maintenance of gingival margin at same level as its homolateral

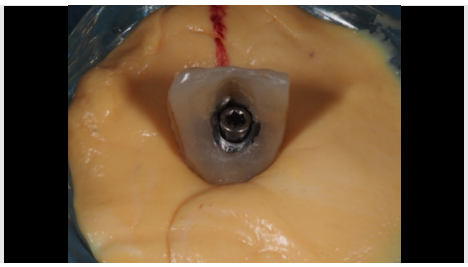

Creation of a personalized transfer abutment from provisional piece

CLINICAL CASE

## Creating emergence profiles in immediate implant dentistry

After 4 months, a personalized impression was taken by means of a customized flow closed tray transfer according to the emergence profile obtained with the provisional piece [8, 9] and a final ceramic-metal crown screwed to the implant was created using CAD-CAM (Core3dcentres).

Emergence profile formed in silicone matrix to create personalized transfer abutment



Light-curing of resin to recreate emergence profile of provisional piece



Personalized transfer abutment with Ocean titanium implant holder

Insertion of personalized transfer abutment

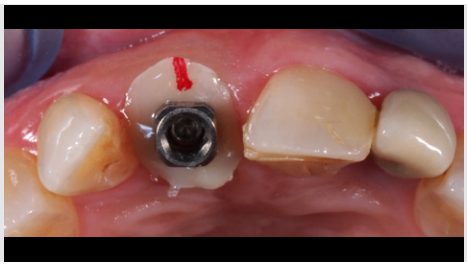

Occlusal view of personalized transfer abutment positioned in mouth

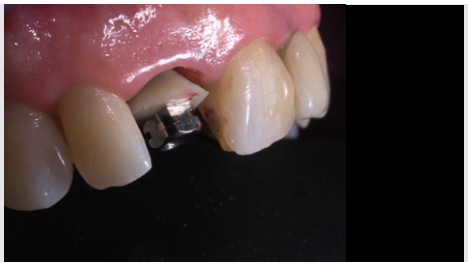

Detail of personalized transfer abutment positioned in mouth

CLINICAL CASE

## Creating emergence profiles in immediate implant dentistry

Shade of final prosthesis against black background

Fully integrated final porcelain-metal crown

View of gingival maintenance and architecture

Detail of perfectly integrated crown showing straight correct emergence profile

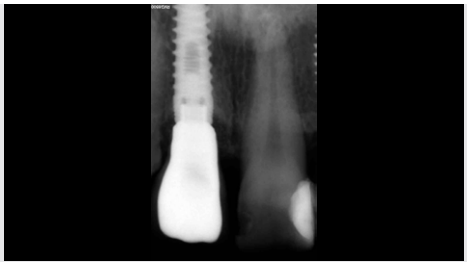

Panoramic X-ray at the time of positioning final crown showing no crestal bone loss

## BIBLIOGRAPHY

1. Araújo MG, Sukekava F, Wennström JL, Lindhe J. Ridge alterations following implant placement in fresh extraction sockets: an experimental study in the dog. J. Clin Periodontol 2005; 32: 645-652.

2. Kan JY, Rungcharassaeng K, Lozada J. Immediate placement and provisionalization of maxillary anterior single implants: 1-year prospective study. Int J Oral Maxillofac Implants, 203; 18: 31-39.

3. Chen ST, Wilson TG Jr, Hämmerle CH. Immediate or early placement of implants following tooth extraction: review of biologic basis, clinical procedures, and outcomes. Int J Oral Maxillofac Implants 2004; 19 (suppl): 12-25.

4. Hämmerle CH, Chen ST, Wilson TG Jr. Consensus statements and recommended clinical procedures regarding the placement of implants in extraction sockets. Int J Oral Maxillofac Implants 2004; 19 (suppl): 26-28.

5. Cornellini R, Cangini F, Covani U, Wilson TG Jr. Immediate restoration of implants placed into fresh extraction sockets for single-tooth replacement: a prospective clinical study. Int J Periodontics Restorative Dent 2005; 25; 439-447.

6. Esposito M, Grusovin MG, Willings M, Coulthard P, Worthington HV. Interventions for replacing missing teeth: different times for loading dental implants. Cochrane Database Syst Rev 2007; 18: CD003878.

7. Su H, Gonzalez-Martin O, Weisgold A, Lee E. Considerations of implant abutment and crown contour: critical contour and subcritical contour. Int J Periodontics Restorative Dent. 2010 Aug; 30(4): 335-43.

8. Hinds KD. Custom impression coping for an exact registration of the healed tissue in the esthetic implant restoration. Int J Periodontics Restorative Dent. 1997 Dec; 17(6): 584-91.

9. Papadopoulos I, Pozidi G, Goussias H, Kourtis S. Transferring the emergence profile from the provisional to the final restoration. J Esthet Restor Dent. 2014 May-Jun; 26(3): 154-61. doi: 10.1111/jerd.12068. Epub 2013 Dec 17.